

## Wrist Osteoarthritis

M. Merle and Ph. Voche

- Pathogenesis
- Surgical Options for Radiocarpal and Intercarpal Arthritis
- Surgical Options for Ulnar Abutment and Distal Radioulnar Joint Arthritis
- Selection of Appropriate Surgical Procedure
- Denervation of the Wrist

Primary osteoarthritis of the wrist remains a nebulous entity, as doubt still exists regarding the etiology, be it traumatic, unknown or neglected. Admittedly chondrocalcinosis, by itself, can alter all the articulations of the wrist but it is usually seen only in arthritis of the scaphotrapezoido-trapezium (STT) joint. The pathogenesis of osteoarthritis is better known. Ageing of the chondrocytes causes a diminution of their ability to synthesize, which is indispensable for the repair of cartilage. The role of cytokines and in particular, interleukin-1 beta (IL-1 $\beta$ ) combined with TNF- $\alpha$ , causes catabolic activity at the level of the cartilage.<sup>1</sup> This explains why some authors utilize, as in rheumatoid arthritis, anti-TNF- $\alpha$  to slow down this destructive process. Treatment of the ageing chondrocytes themselves could be targeted in the near future by the use of interleukin-1RA which blocks the activity of IL-1 $\beta$ . Concurrently, MR imaging of affected cartilage has progressed considerably and allows a much earlier diagnosis than conventional radiographs.

Patients who suffer from a degenerative, painful wrist require a therapeutic solution which provides a compromise between mobility, strength and comfort. The hip, knee and shoulder joints have benefited spectacularly from prosthetic surgery. However, the

biomechanic complexity of the wrist has not permitted the same advances.<sup>2,3</sup> This difficulty has prompted hand surgeons to propose a range of procedures: synovectomy, styloidectomy, denervation, ligamentoplasty, partial or total arthrodesis, and partial or total arthroplasty. If these treatments are accurately evaluated, it would be evident that there is no surgical procedure which allows perfect restoration of wrist function. Ideally, joint consultations by surgeons and rheumatologists would allow patients to have the benefit of early management, diagnosis and treatment. For example, allowing the progress of a SLAC (scapholunate advanced collapse) wrist to stage III, amounts to condemning the wrist to irreversible loss of function.

### Pathogenesis

---

#### Radiocarpal and Intercarpal Arthritis

Linscheid *et al.* observed that carpal bone deformities and the development of instabilities were the result of degenerative and traumatic rupture of radiocarpal and intercarpal ligaments.<sup>2,3</sup> The loss of

links between the carpal bones causes a profound disorganization of the mechanical equilibrium, particularly at the level of the scaphoid, when the scapholunate ligament is no longer competent. Following a relatively asymptomatic period, the clinical picture changes with the emergence of pain, reduction in mobility with intracarpal instability and a diminution of strength. The first signs of cartilage degeneration will appear between the scaphoid and radial styloid, presenting, according to Watson and Ballet, a SLAC wrist at stage I<sup>4</sup> (Fig. 1.1). In stage II, the progression of cartilage damage is evident at the radioscaphoid level, with scapholunate dissociation and the appearance of osteophytes. Stage III shows a disappearance of the radioscaphoid joint and arthrosis of the capitulum joint, with only the radiolunate articulation being spared.

When there is chondrocalcinosis, the evolution of instability is slightly different and Romano has proposed a classification with six stages, to describe the progression of articular degeneration of what he terms a SCAC wrist (scaphoid chondrocalcinosis advanced collapse)<sup>5,6</sup> (Fig.1.2).

- Stage I: Widening of scapholunate space without rotation of the scaphoid, with subchondral sclerosis of the radioscaphoid joint
- Stage II: Rotation of scaphoid; scapholunate joint widening increases due to pyrophosphate calcium deposits, which alters the scapholunate ligament
- Stage III: Calcification of the triangular ligament and lunotriquetral dissociation
- Stage IV: Destruction of the radiolunate articulation
- Stage V: Isolated alteration of the midcarpal joint
- Stage VI: Global destruction.

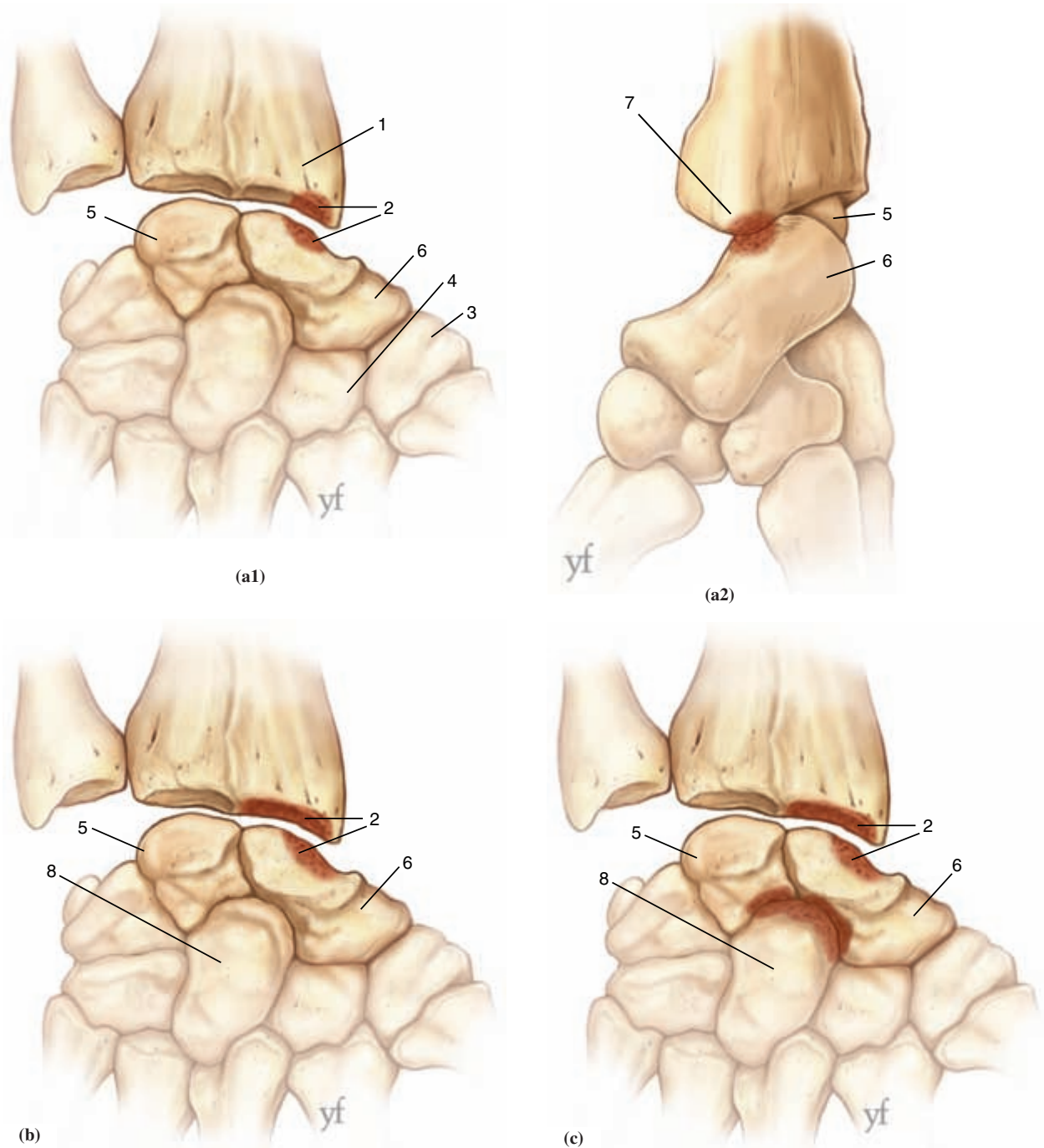
The STT joint may be the site of isolated pain which often requires arthrodesis. Pisotriquetral osteoarthritis, a rarer condition, also requires surgical intervention. These changes require therapeutic

interventions which, at first, consist of a resting splint, non steroidal anti-inflammatory agents and sometimes a corticosteroid articular injection. Very often these first line treatments bring relief to patients who will find their symptoms more tolerable by modifying their activities.

## Ulnar Impaction

Ulnar impaction presents with pain which causes loss of strength and makes carrying out of daily activities difficult. The outlook is more severe as ulnar deviation and wrist extension become affected. When the wrist is loaded, about 80% of force transmission occurs through the radius and 20% through the ulna. Palmer and Werner have shown that, when ulnar variance increases by 2.5 mm, the distribution of forces changes to 58.1% on the radius, 41.9% on the ulna.<sup>25</sup> This explains how ulnar loading alters the triangular ligament and then generates ulnotriquetral chondritis. Palmer has proposed a classification of lesions of the TFCC. Class I deals with traumatic lesions, while Class II deals with degenerative lesions. Class II has been further subdivided into five stages.<sup>26</sup>

- Stage 2A: Thinning of articular disc, but no perforation
- Stage 2B: Thinning of articular disc with chondromalacia of the ulna, lunate or triquetrum
- Stage 2C: Perforation of triangular ligament with chondromalacia of the ulna, lunate or triquetrum
- Stage 2D: Perforation of triangular ligament with chondromalacia of the ulna, lunate or triquetrum and a tear of the lunotriquetral ligament
- Stage 2E: Perforation of triangular ligament with chondromalacia of the ulna, lunate or triquetrum and a tear of the lunotriquetral ligament with ulnocarpal arthritis.



**Figure 1-1.**

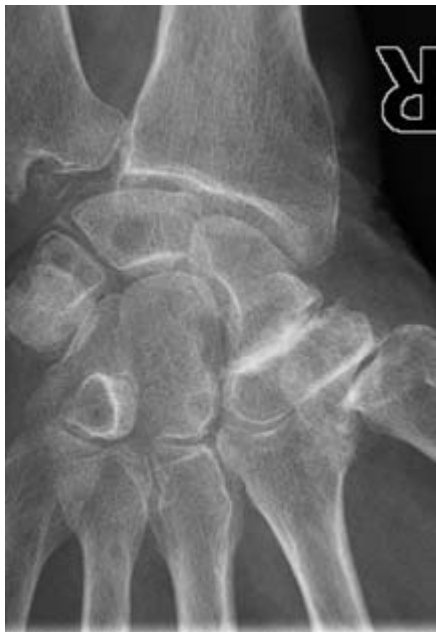The 3 stages of the *SLAC* (scapholunate advanced collapse) wrist.

(a) Stage I: chondritis between the scaphoid and radial styloid.

(b) Stage II: degenerative change of the entire scaphoid fossa, scapholunate dissociation and osteophytic proliferation.

(c) Stage III: disappearance of the radioscaphoid articulation and degeneration of the capitulunate and scaphocapitate articulations.

(1) Radius. (2) Chondritis. (3) Trapezium. (4) Trapezoid. (5) *Lunate*. (6) Scaphoid. (7) Radial styloid. (8) Capitate.



**Figure 1-2.**

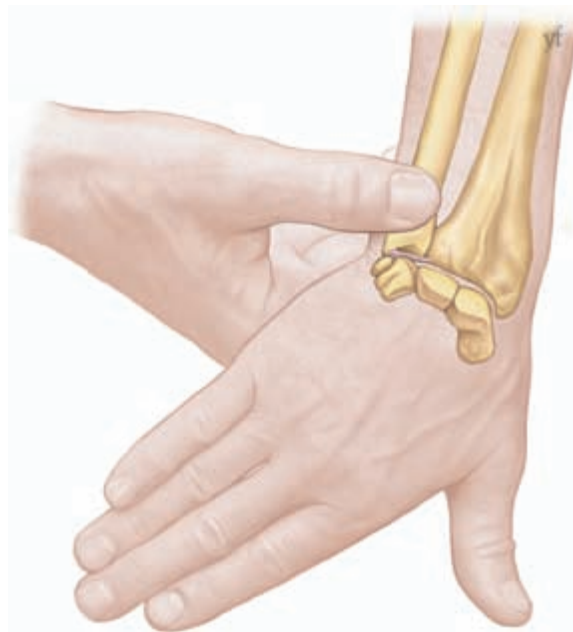Chondrocalcinosis of the wrist. Beginning of scapholunate degeneration without rotation of the scaphoid, severe STT osteoarthritis arthrosis, radioulnar arthrosis and calcium deposits on the triangular ligament.

### **Diagnosis**

Patient presents with pain on the dorsal aspect of the distal radioulnar joint, which is worsened by ulnar deviation of the wrist. The patient may feel a catch and notice a progressive loss of strength and mobility of the wrist. Pain is aggravated when the examiner places the wrist in pronation and in ulnar deviation, and when applying pressure dorsally to the ulnar head (Fig. 1.3). This pain must be distinguished from the one caused by subluxation of the extensor carpi ulnaris (ECU), calcifying tendinitis of the flexor carpi ulnaris (FCU) or the extensor carpi ulnaris, or arthritis of the pisotriquetral joint.

### **Radiological assessment**

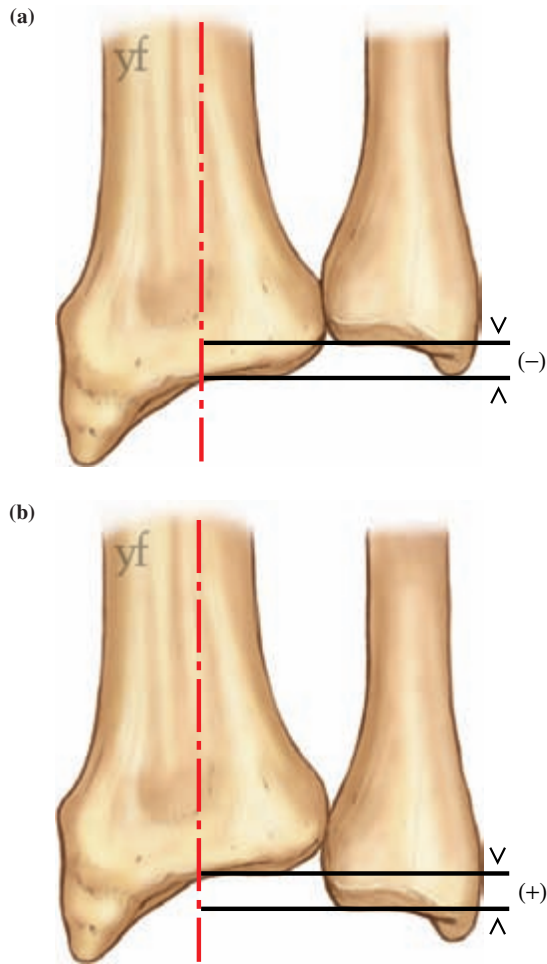
The ulnar variance must be evaluated accurately with radiograph. The X-ray is taken with the arm in 90° of shoulder abduction, 90° of elbow flexion, the forearm in neutral and the palm of the hand laid flat on the radiographical plate, the third



**Figure 1-3.**

Ulnar impaction with degeneration of the triangular ligament is shown clearly when the hand is positioned in pronation, and the wrist in ulnar deviation; pain is aggravated when the examiner applies pressure on the ulnar head.

carpometacarpal being in the axis of the forearm and parallel to the plate, and the beam directed at the metacarpal joint. The variance is determined by projecting a line perpendicular from the carpal joint surface of the distal end of the radius toward the ulna and measuring the distance in millimeters between this line and the carpal surface of the ulna<sup>23</sup> (Fig. 1.4). Palmer prefers to use a transparency, where concentric circles, 20 to 50 mm in diameter, are spaced out at 1 mm intervals.<sup>24</sup> The half circle that best adapts to the articular concavity of the radius is selected. The distance separating it from the one which goes through the distal ulnar pole represents the value in millimetres of the inferior radiocubital index or ulnar variance. Usually, it is slightly negative (−0.9 mm). This protocol must be strictly followed in order to have reproducible measurements. This is because the variance increases if the shoulder is at less than 90° of abduction, or the forearm is in pronation, and if the patient is asked to



**Figure 1-4.**

Evaluation of the distal radioulnar index or ulnar variance: (a) the index is negative; (b) the index is positive.

make a grip. Osteoarthritis of the radioscapholunate joint also increases ulnar variance.

### Distal Radioulnar Joint Arthritis

This condition presents with pain on pronation and supination, and the patient tends to avoid pronosupination activities such as turning a door knob. There is a loss of strength accompanied frequently by instability of the ulnar head dorsally. PA and lateral X-rays will show the degree of subluxation and classic osteophytic proliferation around the head can be seen.

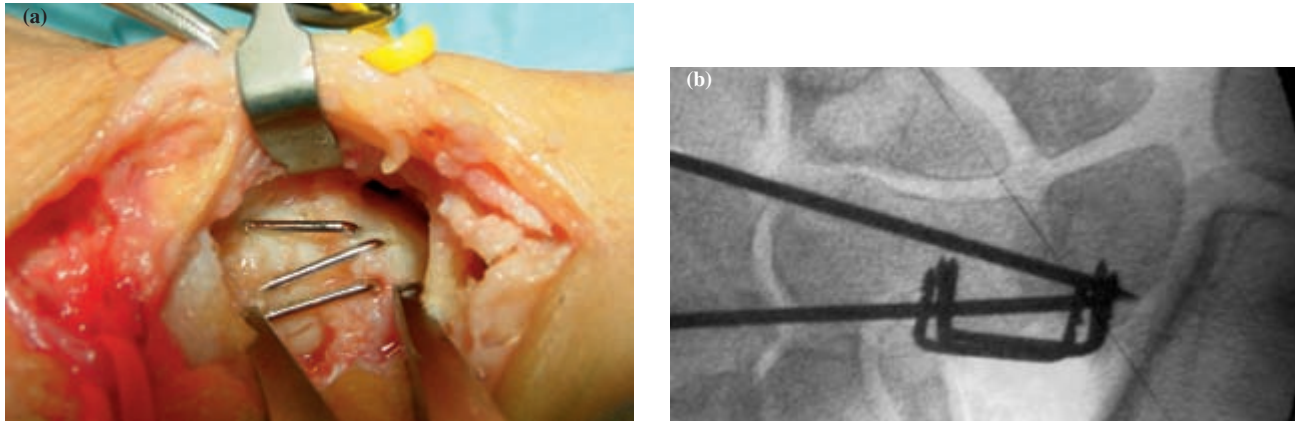
There is, however, no link between the radiological findings and the functional abilities of the patient. It is the emergence of pain restricting daily activities that will lead the patient to seek surgical consultation.

## Surgical Options for Radiocarpal and Intercarpal Arthritis

There are numerous procedures which can be ranked according to their efficacy and these are recommended depending on the stage of the degeneration. Most of the techniques presented here are shown in detail and illustrated in Volume 2.

### Styloidectomy

Styloidectomy is the preferred form of treatment in a stage I SLAC wrist. The surgical approach is done directly above the radial styloid, care being taken to preserve the dorsal branch of the superficial radial nerve. An oblique osteotomy sacrifices the *radiocarpal* ligament but preserves the radioscaphocapitate ligament. The styloidectomy must be economical and not exceed 5 mm. Anything more would incur the subsequent risk of ulnar translation instability. If the *radiocarpal* ligament complex is of good quality, it could be inserted on the radius with a Mitek bone anchor or with the help of a trans-osseous PDS 2/0 suture. Arthroscopic styloidectomy is the technique of choice, as it permits direct assessment of the joint and ligamentous structures, and allows the surgeon to perform an osseous resection without altering the radiocarpal ligament complex. The arthroscope is introduced via the 3–4 portal and a 2.9 mm debrider via the 1–2 portal. The 6 R/u portal is used for abundant irrigation of the articular cavity. In the presence of significant synovitis, a synovectomy by thermocoagulation is performed carefully with the Vaper-Mitek. The adjustment of the electrode intensity has to be very precise in order to avoid any



**Figure 1-5.**

Capitulunate arthrodesis via a lateral radial approach. First, a radial styloidectomy is performed to facilitate a scaphoidectomy of the proximal two-thirds of the scaphoid. Cloward retractor is used for the decortication of the capitulunate articulation. The joint space is filled in with cancellous bone harvested from the scaphoid and distal radius. Fixation is completed with three staples and two *K-wires/Kirshner pins* 15/10 inserted through the second and third intermetacarpal spaces.

damage to the capsuloligamentous structures. The wrist is immobilized in a neutral position, the digits being kept free with a splint for two weeks. Rehabilitation can be started at six weeks.

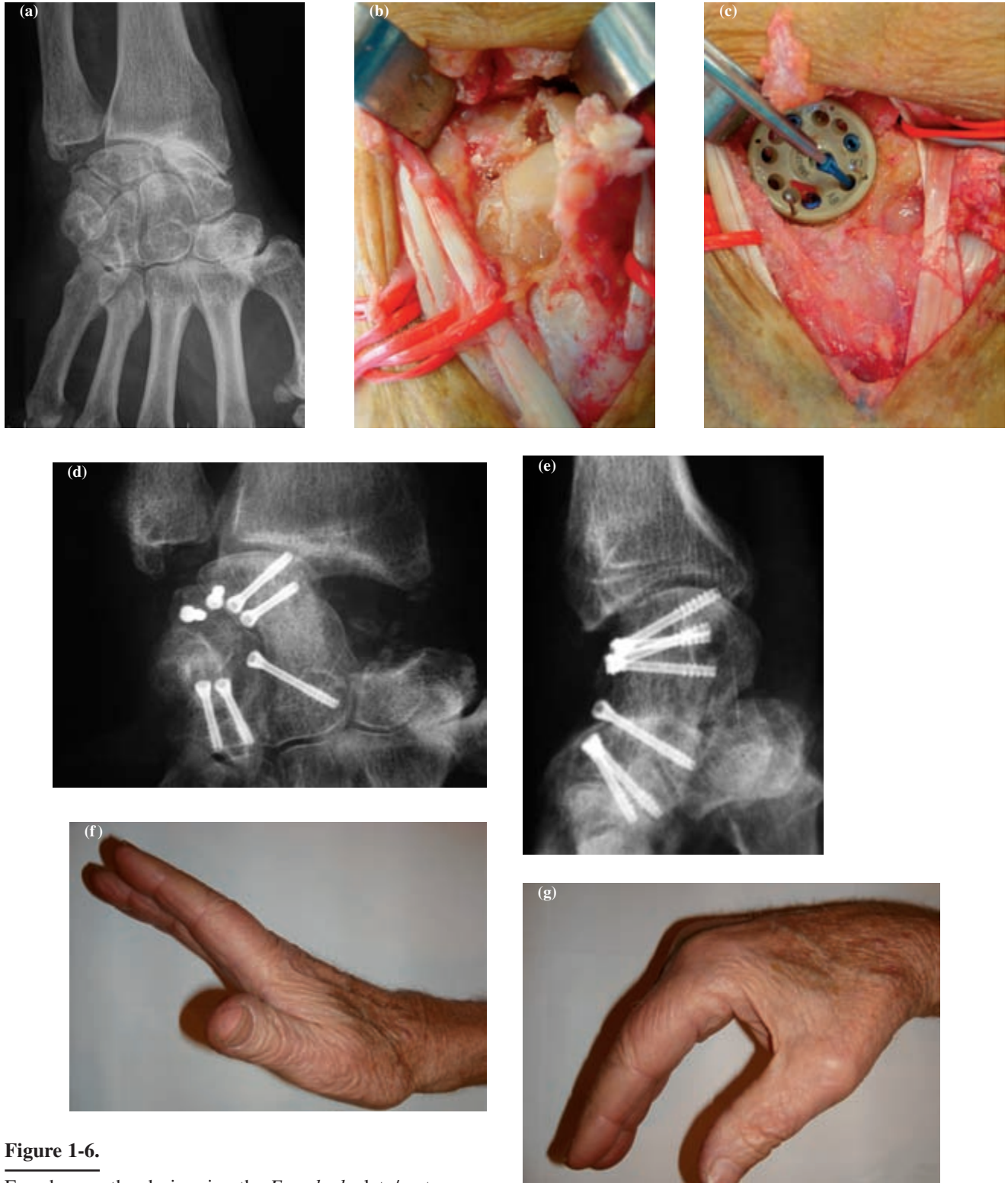
### Scaphoidectomy

This is usually indicated in stage II SLAC/SCAC wrists. It is reasonable to perform a scaphoidectomy of the proximal two-thirds of the scaphoid, if the STT articulation is not affected. If arthritis is present, a total scaphoidectomy is indicated. Force transmission then occurs through the triquetro-lunate complex. Any lunate dorsiflexion of the dorsal intercalary segmental carpal (DISI) should then be reduced and this bone arthrodesed with the capitate. We routinely favor this type of arthrodesis when the ulnar column of the carpal bones is not affected. There are two possible approaches, i.e. radial or dorsoulnar. The radial approach is the more elegant approach: when combined with a styloidectomy, it allows the execution of a partial or complete scaphoidectomy. There is also control of the entire capitulunate articular surface, enabling full visualization of the decortications,

which increases the quality of arthrodesis. Arthrodesis is achieved with wires and staples. This approach allows precise placement of the lunate in a neutral position, or alternatively, in slight extension or flexion, depending on the patient's specific request (Fig. 1.5). However, we have not seen better functional outcome although we assumed that by preserving the dorsal capsuloligamentous complex, we would have less limitation in flexion. In fact, the results are similar to those obtained via the dorsal approach, achieving 60° of flexion and extension and 42° of radial and ulnar deviation.<sup>7,8</sup> The dorsolunar incision has the advantages of allowing better access to the carpal bones, facilitating resection of the posterior interosseous nerve, and allowing the conversion of a capitulunate arthrodesis to a four-corner fusion if the lesions prove to be more extensive, or if the reduction of the ulnar translation of the lunate is impossible to correct.

### Scaphoidectomy with Four-Corner Fusion

Four-corner arthrodesis involves the lunate, triquetrum, capitate and hamate (Fig. 1.6). Our



**Figure 1-6.**

Four-bone arthrodesis using the *Easy lock* plate/system.

(a) SCAC stage II wrist chondrocalcinosis of a patient aged 81.

(b) Calcium deposits have caused degeneration of the capsuloaligamentous apparatus.

(c) Installation of the *Easy Lock* plate with titanium screws.

(d, e) Radiographic view 19 months later.

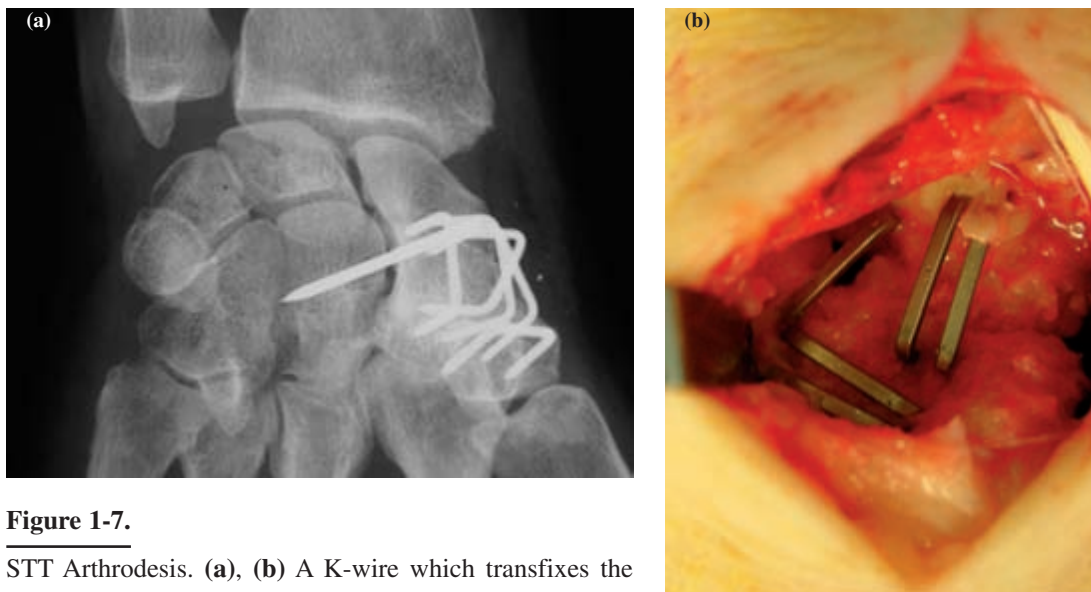
(f, g) Articular amplitudes of 35° flexion-extension.

preferred method remains a curvilinear incision, centered on the third ray. The dorsal capsule is opened via a “H” incision. Scaphoidectomy is partial or total, depending on the condition of the STT joint. Osteosynthesis is performed in the classical manner by pinning and stapling. We have performed a series of 19 fusions using the Biotech International Easy Lock system which is similar to the Spider plate.<sup>9</sup> Our results were comparable to the more traditional techniques and contradict Kendall’s experience.<sup>10,11</sup> Whatever the osteosynthesis technique, reduction of the DISI deformity with a temporary radiolunate wire must be done first. Special care must be taken in the execution of the arthrodesis using a circular plate. One must ensure the proper decortication of all the articular surfaces and addition of cancellous grafts taken from the radial metaphysis as the bone extracted from the scaphoid is insufficient. The circular plate should also remain sufficiently distal from the dorsal edge of the distal radius in order to prevent restricted wrist extension. Finally, the plate should be positioned in such a way that each of the carpal bones can receive two screws. The results of

our arthrodesis are very different from those reported by Ryu *et al.* They reported 40° of extension, 40° of flexion, 30° of ulnar deviation, and 10° of radial deviation.<sup>13</sup> In our first series, we obtained 45° of flexion and extension, and 18° of radial and ulnar deviation.<sup>12</sup> In a second series, we obtained 50° of flexion and extension, and 26° of radial and ulnar deviation.<sup>8</sup>

### STT Joint Arthrodesis

Osteoarthritis of the STT joint is common and has been found in 83.3% of dissected cadavers<sup>14</sup> (Fig. 1.7). In the context of chondrocalcinosis, Safar observed a prevalence of 61.4% of STT osteoarthritis. It can remain asymptomatic for a long time. On the contrary, it can be very painful, forcing the patient to seek a surgical solution.<sup>6</sup> This arthrodesis was first performed in 1967 by Peterson and Lipscomb.<sup>15</sup> Watson and Hempton were early advocates.<sup>16</sup> The technique has been elaborated in Volume 2. In contrast to Watson, we prefer a lateral curvilinear incision from the



**Figure 1-7.**

STT Arthrodesis. (a), (b) A K-wire which transfixes the scaphoid to the capitate is used as an axis of rotation fixed at a radioscapoid angle of 45°. The stability of the structure is ensured with five 3M titanium staples. A radial styloidectomy is performed in conjunction with this arthrodesis in order to avoid any radioscapoid impaction.



anatomical snuff box to the radial styloid, as we systematically perform a styloidectomy, which as described by Voche, allows the harvesting of cancellous bone from the radial epiphysis through the gap left by the styloidectomy.<sup>17</sup> The height of the carpus and a radioscapoid angle of about 45° should be maintained. This adjustment is achieved by a 1.2 mm Kirschner wire (K-wire), drilled transversely into the middle of the scaphoid and transfixed to the capitate. It is a mistake to extend the scaphoid too much as it increases the stress on the scaphoid fossa of the radius, causing pain and stiffness. Strict immobilization of the wrist is required for six weeks. This procedure gives consistent outcome with regard to pain reduction, when the arthritis is limited to the STT joint. The following amplitudes can be expected: flexion and extension, 91°; radial deviation, 0°; and ulnar deviation, 30°.

### Scaphocapitate Arthrodesis

As primary osteoarthritis is a progressive disease, scaphocapitate (SC) arthrodesis is not used for its treatment. The development of primary osteoarthritis of the wrist is not a surgical indication as by arthrodesing this complex, we would be assuming that osteoarthritis is a non-progressive disease. Therefore, SC must be reserved only for a traumatic stage I SLAC wrist, when the scapholunate ligament can no longer be repaired.

### Radiolunate or Radioscapholunate Arthrodesis

This arthrodesis must be reserved for a rheumatoid wrist (Chap. 5), as primary osteoarthritis of the wrist is seldom limited to the radiocarpal joint and loading of the midcarpal joint will eventually cause significant pain. In rheumatoid polyarthritis, the capsuloligamentous apparatus is altered and distended due to the disease, which results in a 50° range of mobility. The original range of motion is never regained in a wrist following radioscapholunate arthrodesis.

### Proximal Row Carpectomy

In primary osteoarthritis, a surgical indication for proximal row carpectomy is limited as the capitate and lunate fossae are rarely free of chondromalacia. An arthroscopy or an MRI is essential for an evaluation of the articular surface before a decision is made whether to proceed with a proximal row carpectomy. A scaphoidectomy with a 4-corner fusion is an alternative.

### Pisotriquetral Arthrodesis

Though the most common cause of pisotriquetral arthritis is trauma, this condition may also arise in the presence of chondrocalcinosis. There is significant pain and loss of strength. Diagnosis is confirmed by placing the wrist in flexion to relax the flexor carpi ulnaris (FCU) and by using the thumb and index finger to move the pisiform side to side in a radial-ulnar direction. This should reproduce the pain or crepitus. Under great stress by the FCU, the pisiform transmits forces through the triquetro-hamate ligament which interlinks both rows of carpal bones. Spatial mobility of the pisiform is important as biomechanical studies have proven that it acts as a stabilizer for the triquetrum and prevents ulnocarpal translation.<sup>19</sup> Therefore, it is recommended to preserve the bone and to perform an arthrodesis rather than an excision, which could also provoke the development of an ulnar nerve neuritis. Pisotriquetral arthrosis should first be treated medically. A static splint should be applied to the neutrally positioned wrist, followed by NSAIDs and eventually by injecting corticosteroids into the joint. This treatment is often effective and helps to delay the need for an pisotriquetral arthrodesis for significant period of time.

A curvilinear incision is made over the Guyon's canal and extends around the pisiform. This approach allows for greater control of the ulnar nerve and artery. The tendinous and capsuloligamentous complex is incised transversely on the radial side of the pisiform. Chondritis is clearly seen on both the

articular surfaces. Resection is performed up to the sub-chondral bone with a rongeur. Following this, a 1 mm K-wire is used to fix the pisotriquetral complex temporarily. Osteosynthesis is achieved with two 1.2 mm diameter screws inserted slightly divergent from each other. A splint is applied to the wrist in 20° extension for four weeks to ensure immobilization, so as to minimize traction by the FCU (Fig. 1.8).

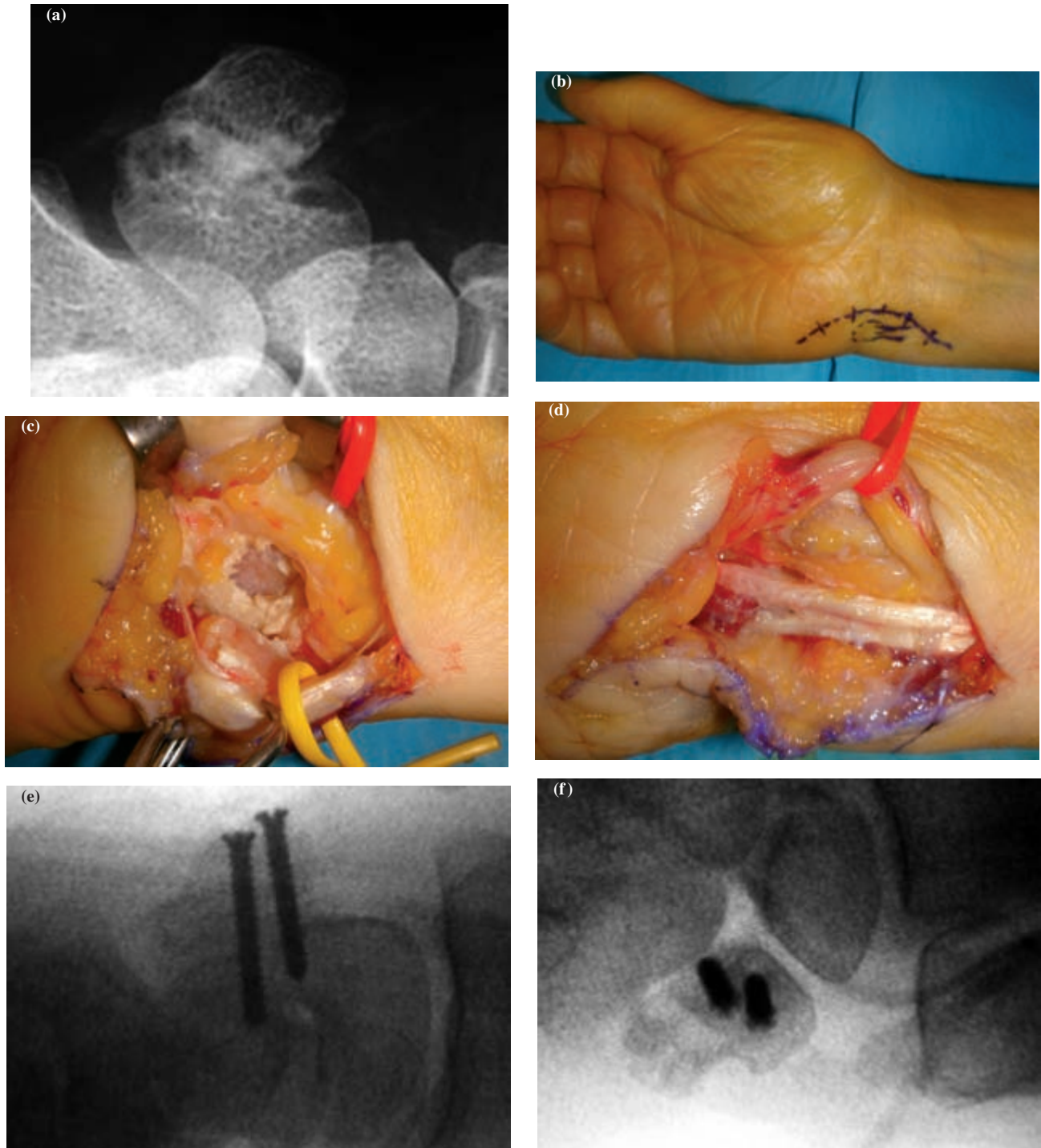
### Total Wrist Arthroplasty

There remains an unresolved problem. All attempts at total wrist arthroplasty have ended more often than not by removal of the prosthesis, making the eventual arthrodesis more difficult to execute as radiocarpal resection is required. In 1967, Swanson developed a Silastic implant which he would later encase in a titanium sleeve to reduce migration into the radius and distal carpal row.<sup>20</sup> Despite the reduction of pain, the range of motion deteriorates with time and has led to all the teams abandoning the use of this implant. Since then, there have been numerous attempts at unconstrained arthroplasties by Volz, Meuli, the Mayo Clinic (Bi-axial), the Guepar group, etc. Many complications have been observed. Lucency first appears around the carpal implant with erosion of the cortex. Eventually the implant perforates through the cortex and migrates into the metacarpal space. The musculotendinous complex which steers the whole prosthesis is then subjected to severe mechanical stress and the wrist extensors are prone to rupture. The rupture of the extensor carpi radialis longus (ECRL) and the extensor carpi radialis brevis (ECRB) causes the wrist to go into ulnar deviation and the prosthesis to sublux. Revision surgery is difficult and new complications arise which eventually leads to a definitive arthrodesis. For patients who cannot submit themselves to a total wrist arthrodesis, we interpose a 2 mm sheet of silicone in the radiocarpal articular space to provide relief to joint pain. The lifespan of this type of

arthroplasty varies from a few months to a few years (Vol. 2, Chap. 5, Fig. 59a, etc).

### Total Wrist Arthrodesis

This is indicated when osteoarthritis of the wrist progresses to a late stage; pain is significant, and normal daily activities become difficult. There are numerous techniques which can be used for treatment and these have been discussed in Chap. 5, Vol. 2 (1995), pp. 443–447. We favor the technique of osteosynthesis using plates and screws as developed by Synthes, for it permits complete arthrodesis without the need for an iliac crest bone graft (Fig. 1.9).<sup>21</sup> This arthrodesis must be complete and should involve not only the radiocarpal and ulnocarpal joints, but also the carpometacarpal joints of the 2nd and 3rd rays. A longitudinal incision is made over the dorsum of the wrist, starting at the radial edge of the third metacarpal and extending towards Lister's tubercle and the distal part of the radius. The transverse venous branches are ligated and the third compartment is incised in order to free the extensor pollicis longus (EPL), and to transpose it to the radial side of the wrist. The extensor retinaculum is reflected and preserved during the whole procedure, to be repaired at the end so as to avoid bowstringing of the extensor tendons. The articular surfaces, which are to be fused, must be rawed down to cancellous bone. With an osteotome, the distal radius including Lister's tubercle, the lunate, scaphoid and capitate and the third metacarpal are decorticated dorsally. This bone and the underlying cancellous bone are used to pack the rawed articular surfaces. Synthes offers three types of titanium plates, of which two are prebent. The plates and screws are low profile so as to minimize irritation of the extensor apparatus. The two prebent plates can be positioned deep into the carpus, when a decortication has been done. They are fixed, maintaining the wrist at 10° of extension. The straight plate is used for difficult arthrodesis that needs an intercalary graft. The distal part of the plate is fixed onto the 3rd



**Figure 1-8.**

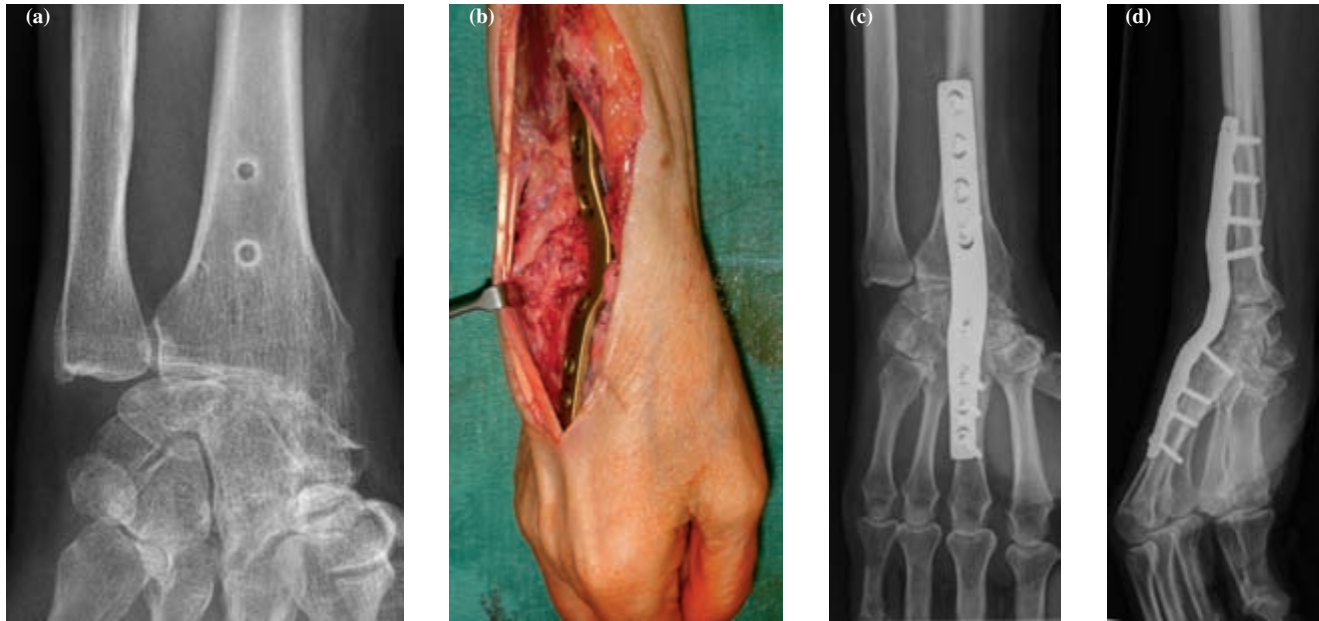
Pisotriquetral arthrodesis.

(a) Pisotriquetral chondrocalcinosis.

(b) A curvilinear incision is made on the radial side on the anterior cubital and extends over the pisiform in order to access the content of Guyon's canal.

(c) The pisiform is retracted anteriorly. There is total articular destruction; calcium deposits are seen around articular areas.

(d, e, f) The arthrodesis is fixed with two 1.7 mm diameter titanium screws inserted through the anterior cubital.



**Figure 1-9.**

Total wrist arthrodesis by Synthes plate.

(a) Failure of an attempt at plate (4 screws!) on stage III *SLAC* wrist.

(b) Reprised by prebent plaque positioned on the third metacarpal and the capitate with 2.7 mm screws and on the radius with 3.5 mm screws.

(c, d) Total fusion in the second month postop.

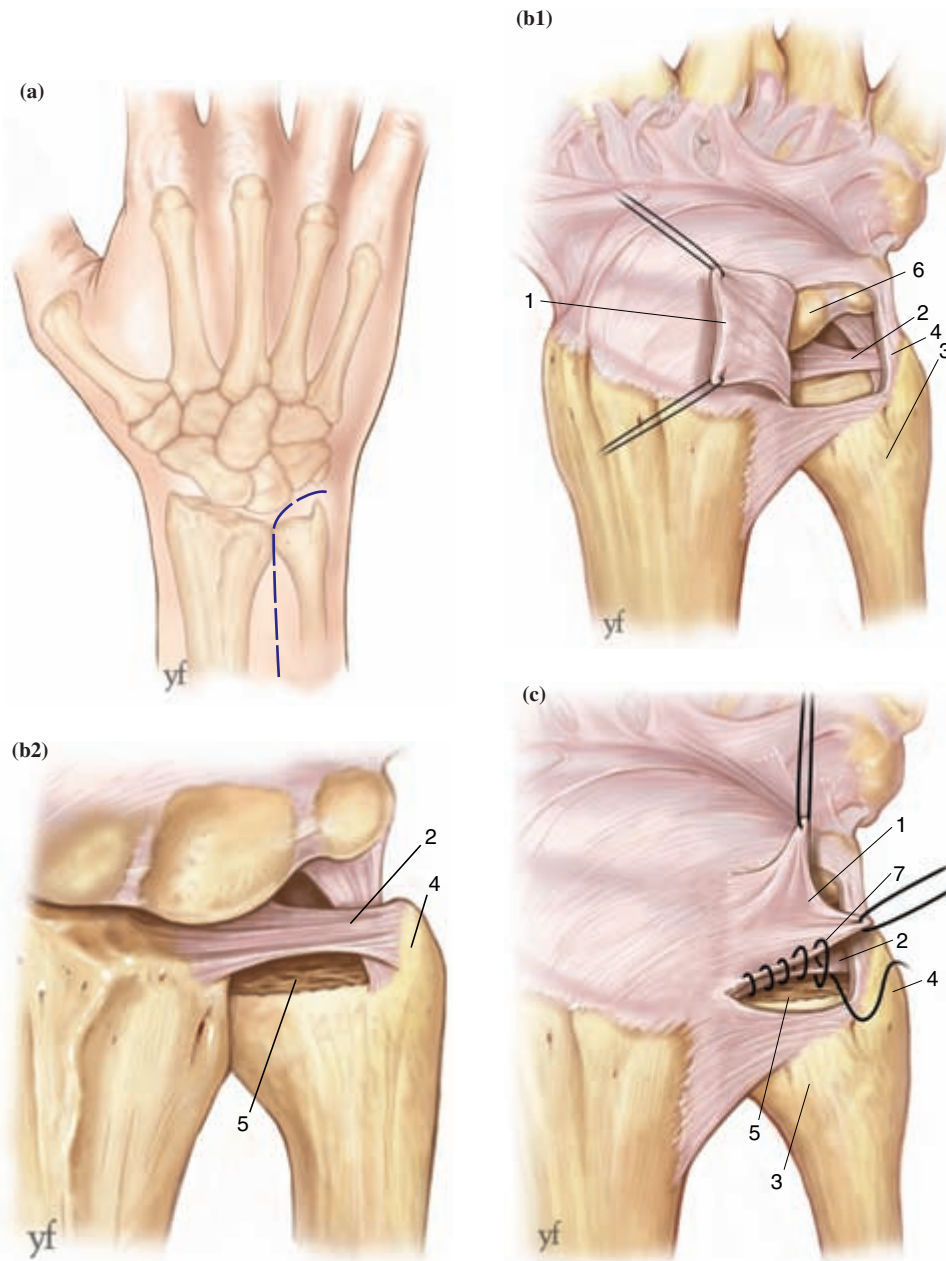
metacarpal with 2.7 mm screws, which are of the same diameter as those used to fix the capitate. The proximal part is fixed to the radius with 3.5 mm screws. It is recommended to give a slight ulnar deviation to the wrist. The plate works by compression; therefore, it is advisable to pack the decorticated articular spaces with cancellous bone graft before applying the plate on the radius. The extensor retinaculum is sutured with PDS 2/0 and a drain is placed for 48 hours. The forearm is maintained in elevation to limit postoperative edema, which is always significant despite the use of compressive bandaging and a vacuum drain. On the third postoperative day, the vacuum drain is removed and a protective forearm based splint, which allows digital mobilization, is applied for four weeks. By the 6th week, light work is allowed and by the 12th week, the patient can return to work. In our series of 16 cases, we have always obtained fusion, except for one case where micromovements of the 2nd carpometacarpal joint remained. In 10 cases, we needed to

remove the implant because of discomfort at the level of the extensor apparatus. Complete resolution of pain was obtained in only nine out of the 16 cases. All the patients who had undergone more than two interventions before definitive arthrodesis, continued to have intermittent, sporadic wrist pain. However, they all regained sufficient strength to carry out their daily activities. These results are similar to those obtained by Hastings.<sup>22</sup>

## Surgical Options for Ulnar Abutment and Distal Radioulnar Joint Arthritis

### Wafer Procedure

This procedure described by Felden *et al.* is intended for moderate ulnar impaction, where ulnar variance does not exceed 4 mm (Fig. 1.10).<sup>27</sup> It



**Figure 1-10.**

*Wafer procedure* performed as an open procedure.

(a) A longitudinal dorsal incision is made on the radial edge of the ulna and extended in a curved fashion towards the ulnocarpal space.

(b) A radially based U-shaped flap is raised to expose the distal radioulnar joint, 2 to 4 mm of the distal ulnar head are resected with an osteotome while preserving the ulnar styloid process and the ligaments attached to it.

(c) The capsular flap is sutured with 2/0 PDS to the dorsal part of the triangular ligament.

(1) U-shaped capsular flap *based radially*. (2) triangular ligament. (3) ulna. (4) ulnar styloid (5) *area* of the resection of the ulna 2 to 4 mm thick. (6) Triquetrum. (7) suture of the capsular flap to the dorsal part of the triangular ligament.

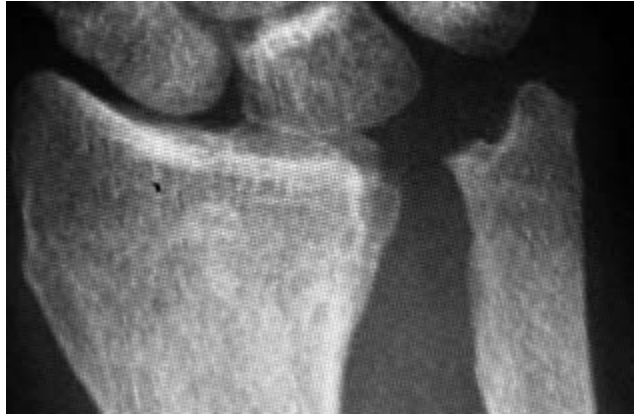involves the resection of 2–4 mm of the distal ulnar head while preserving the radioulnar attachments of the triangular ligament. A dorsal incision is made on the radial edge of the ulna, which is extended in a curved fashion towards the ulnocarpal space. To avoid any residual tendinitis, the ECU is left in place. A radially based U-shaped flap is raised to expose the distal radioulnar joint, the TFCC and the articular surfaces of the lunate and triquetrum. With an osteotome, 2 to 4 mm of the distal ulnar head is resected while the ulnar styloid ligamentous attachments and the TFCC are preserved. At least 50% of the radioulnar articular surface should be preserved. Depending on the degree of alteration to the central part of the TFCC, it can be excised without instability being created. The articular capsule is sutured with 2/0 PDS to the dorsal part of the TFCC and the retinacular ligament is also repaired. A static splint is applied for 3 weeks and daily activities are resumed after the 6th week. This well tested procedure has greatly benefited from arthroscopy. Tomaino and Weiser have reported an improvement of 12 cases operated via introducing the arthroscope through the 3–4 portal and the 2.9 mm debrider through the 6th portal.<sup>28</sup> The arthroscopic resection is made through the triangular ligament, while at the same time preserving its peripheral radioulnar attachments. It is worth noting that arthroscopy reduces surgical trauma of the surrounding structures and allows for earlier mobilization.

### **Ulnar Shortening (Milch<sup>29</sup>)**

This procedure is used exceptionally in wrist osteoarthritis and is only justified for ulnar impaction which requires more than 4 mm of ulnar shortening.

### **Hemiresection-Arthroplasty with Tendon Interposition (Bowers<sup>33</sup>)**

This technique involves an oblique resection of the ulnar head, while preserving the styloid and its



**Figure 1-11.**

Bower's hemiresection tendinous interposition arthroplasty for chondritis limited to the distal radioulnar joint. The gap with the radius is preserved by the interposition of the tendinoplasty taken from half of the ECU tendon. Fluoroscopy is useful to judge impingement.

ligamentous attachments. To avoid radial translation of the ulna, Bowers interposed half of the ECU tendon. This operation is meant for low demand patients suffering from primary osteoarthritis (Fig. 1.11).

### **Ulnar Head Resection (Darrach<sup>30</sup>)**

This proves to be an effective intervention for pain and for the re-establishment of pronosupination. However, it reduces hand grip strength by 25% to 30% and predisposes the carpus to ulnar translation. Moreover, a ligamentoplasty of the FCU from the posterior ulna must always be performed, so as to limit a painful dorsal subluxation of the ulna. (Vol. 2 (1995), Fig. 14.6, pp. 328–329.)

### **Intentional Pseudoarthrosis (Sauve-Kapandji<sup>31</sup>)**

This is the most elegant and effective operation as it preserves the width of the wrist and the ulnocarpal ligamentous complex, while restoring pronosupination,

thus eliminating ulnar impaction. The only problem with this procedure is the stabilization of the proximal ulna (Fig. 1.12). (Vol. 2 (1995), Figs. 14.7 and 14.8, pp. 329–330.)

## Total Arthroplasty

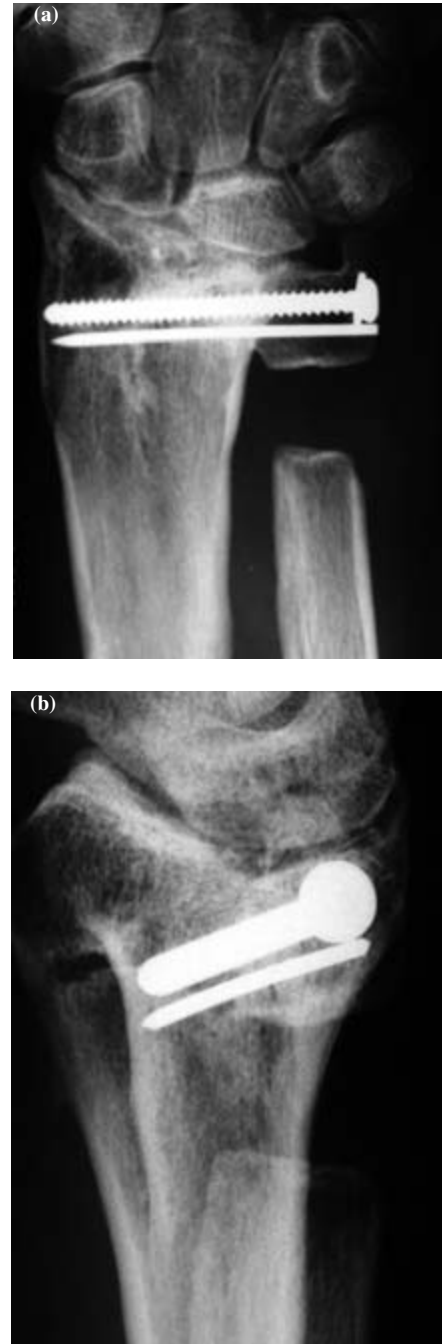
The goal is to re-establish a biomechanically stable joint with metallic implants at both the radioulnar and ulnocarpal joint.<sup>32</sup> Our experience with this procedure has proved to be disappointing, as ligamentoplasty is unable to provide durable stability of the implant in pronosupination.

## Selection of Appropriate Surgical Procedure

### Radiocarpal Osteoarthritis

The surgical recommendations are based on the stage of the SLAC wrist.

- Stage I. Radial styloectomy is normally performed, preferably arthroscopically, with or without synovectomy.
- Stage II. A partial or total scaphoidectomy is carried out depending on the state of the STT joint. It is completed by a capitulate arthrodesis or a four-corner fusion, if osteoarthritis has involved the midcarpus. A total denervation of the wrist can be performed too, depending on the severity of pain. Radioscapholunate arthrodesis with preservation of the ulnocarpal joint poses a risk, as it does not make provisions for an eventual progression of primary osteoarthritis. This procedure should be reserved only for the rheumatoid wrist.



**Figure 1-12.**

Sauve-Kapandji's intentional pseudoarthrosis. Stage II *SLAC* wrist with severe chondritis of the distal radioulnar joint. The portion of the arthrodesed ulnar head should be as short as possible but sufficient to place a 3.5 mm cancellous/*rondelle* screw and a 15/10 K-wire to prevent rotation.

Stage III. A temporary solution consists of interposing a sheet of silicone in the radiocarpal joint space together with total denervation of the wrist. Total arthrodesis of the wrist involving the use of a fusion plate as described by Hastings, is the most effective method as it avoids the morbidity associated with harvesting bone from the iliac crest. Total wrist arthroplasties do not lead to a satisfactory functional outcome in the mid-term, considering the high rate of complications.

### Isolated osteoarthritis of the STT joint

Arthrodesis using staples is the treatment of choice, care being taken not to excessively verticalize the scaphoid. A radial styloidectomy is performed as well.

### Ulnar impaction and distal radioulnar osteoarthritis

The arthroscopic wafer procedure permits the resolution of ulnar impaction, which requires a resection of less than 4 mm of the ulnar head. If greater than 4 mm of ulnar resection is required and arthritis is limited to the ulnocarpal joint, extra-articular shortening of the ulna as described by Milch is the procedure of choice. When ulnar impaction is associated with radioulnar osteoarthritis, hemi-resection with tendinous interposition of part of the ECU as described by Bowers can be proposed to patients whose daily activity requirements are reasonable. We have abandoned this technique in traumatic etiologies due to the progressive migration of the ulna towards the radius, as the latter causes a new impingement despite the interposition of tendinoplasty, which gets ejected like a cherry stone. Proximal denervation of the posterior interosseous nerve remains useful as it helps to improve the patient's discomfort. Severe osteoarthritis of the distal radioulnar joint associated with chondromalacia of the triquetrum requires resection of the ulnar head, according to

Darrach, with ligamentoplasty for stabilization of the ulna by using half of the ECU or FCU. However, our preference is for intentional pseudoarthrosis or Sauve-Kapandji operation which preserves the width of the wrist and limits the risk of ulnar translation of the carpal bones. One of the difficulties remains the stability of the proximal part of the ulna.

## Denervation of the Wrist

---

Denervation of the wrist is an integral part of the surgical armamentarium for chronic wrist pain. The technique and its indications must be specific so as to obtain consistent outcomes. Based on anatomical studies,<sup>25</sup> then on Wilhem's clinical applications,<sup>26</sup> this procedure has been used exclusively by German and Scandinavian practitioners for a long time.

### Anatomy

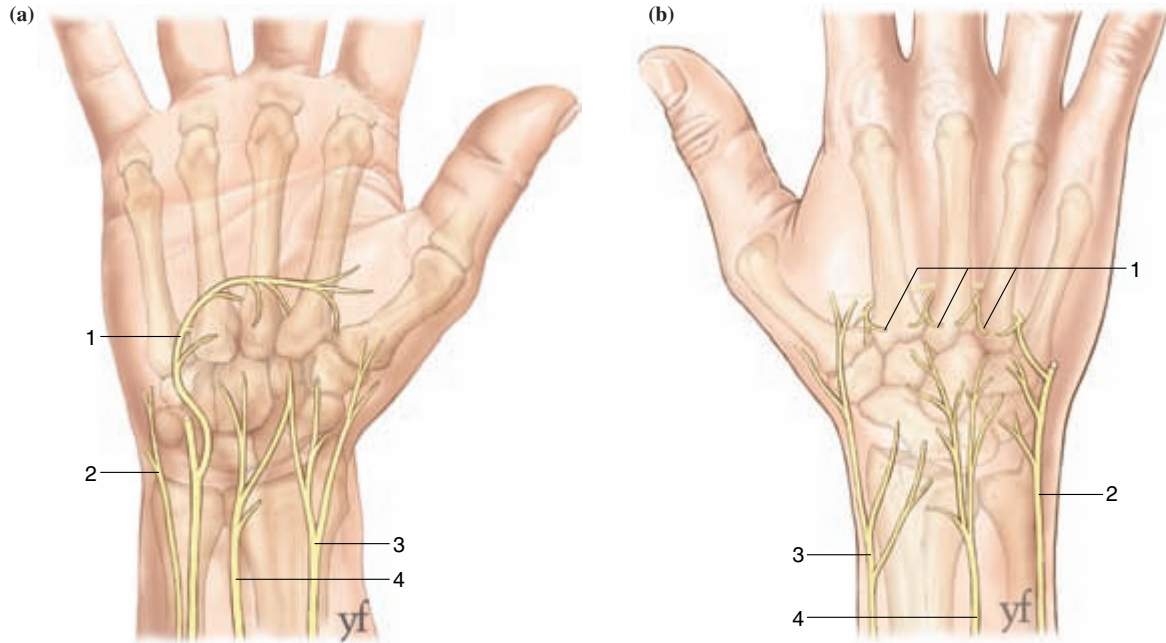
It is essential to be knowledgeable about afferent nerves of the wrist articular complex in order to understand this procedure. Wilhem's first study performed on five adult wrists remains the reference.<sup>25</sup> Ten nerve branches supplying the wrist joint are described (Fig. 1.13).

#### *Radial nerve*

##### *Posterior interosseous nerve*

It is constant and averages 1.4 mm in diameter at the level of Lister's tubercle. It is thus perfectly visible and easily identified. In its distal part, the nerve is accompanied by the terminal dorsal branch of the anterior interosseous vessels. This neurovascular mass, covered with a thick fascia, runs flattened upon the periosteum on the floor of the radial side of the fourth extensor compartment.<sup>20</sup> Some authors describe a constant collateral branch which supplies the distal radioulnar joint. It appears 3 to 5 cm proximal to the distal radioulnar joint space.<sup>5</sup> The terminal branch enters the capsule at the level of the joint line





**Figure 1-13.**

The different nerve branches participating in the innervation of the wrist articular complex.

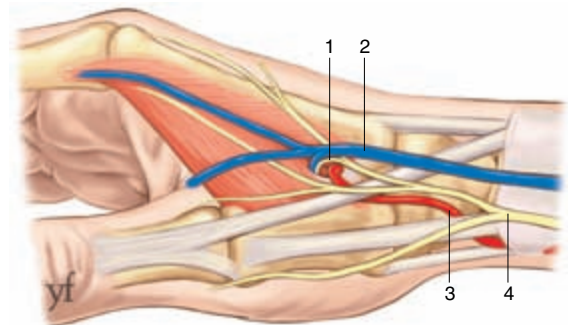
(a) *Palmar side.* (1) muscular terminal branch of the ulnar nerve. (2) dorsal sensory branch of the ulnar nerve. (3) palmar-cutaneous branch. (4) anterior interosseous branch.

(b) *Dorsal side.* (1) terminal muscular branches of the ulnar nerve innervating the carpometacarpal joints. (2) dorsal sensory branch of the ulnar nerve. (3) superficial sensory branch of the radial nerve. (4) posterior interosseous nerve.

and branches out into 3 to 4 ramifications. The area of distribution is wide: lunate, hamate, triquetrum, ulnar head and the first three carpometacarpal joints.<sup>8</sup> It undergoes numerous anastomoses with the articular perforating ramifications of the deep muscular branch of the ulnar nerve, ramifications of the dorsal cutaneous branch of the ulnar nerve, and ramifications of the superficial sensory branch of the radial nerve.

#### *Superficial sensory branch of the radial nerve*

Very fine articular ramifications originate from the three dorsal cutaneous nerves of the superficial sensory branch of the radial nerve. From the surface, they travel with the vessels connecting the subcutaneous and deep venous networks to reach the deep structures. An articular nerve of the first interosseous space, as described by Winckler, arises from the dorsal radial



**Figure 1-14.**

Connections and anatomical details of the nerve trajectory of the first interosseous space (1). *Connecting vein* of the first interosseous space (2). Radial artery (3). Dorsal sensory branch of the radial nerve (4).

nerve of the index finger<sup>27</sup> (Fig. 1.14). It is Foucher's recurrent branch and appears, on an average, 2.6 cm distal to the tip of the radial styloid.<sup>16</sup> Its diameter averages 0.8 mm, which makes it visible during surgery.

Its specific territory is large — trapeziometacarpal joint, thumb and index metacarpophalangeal, and trapeziotrapezoid joint. Throughout its course, it accompanies the venae comitantes of the first dorsal metacarpal artery. The vessels and nerve go through an elliptical perforation of the dorsal aponeurosis located at the top of the interosseous dorsal space. The dorsal cutaneous nerve of the forearm also sends very thin ramifications to deeper structures.

### ***Ulnar nerve***

The nerve trunk gives off, just distal to the ulnar head, an inconstant pisohamate branch. The deep branch of the ulnar nerve gives off branches, which perforate the last three interosseous spaces. Following their course from palmar to dorsal, they enter dorsally and supply the carpometacarpal joints of the four digits. The dorsal cutaneous branch of the ulnar nerve gives off three dorsal cutaneous nerves from which arise very fine articular ramifications. They extend from the surface towards the deeper structures together with the vessels, which link to the deep subcutaneous venous networks.

### ***Median nerve***

#### *Anterior interosseous nerve*

Located at the distal forearm, it averages 1.3 mm in diameter and is accompanied on its ulnar edge by the terminal palmar branch of the anterior interosseous vessels.<sup>16</sup> This neurovascular axis follows its course (closely related to the interosseous membrane) under the pronator quadratus (PQ), which it innervates and vascularizes. Numerous thin terminal branches ramify at the distal edge of this muscle along the whole breadth of the radial epiphysis, of which a medial branch is designated for supplying the distal radioulnar joint. Anastomoses are described with the lateral cutaneous nerve of the forearm and the perforating articular ramifications of the deep muscular branch of the ulnar nerve. The palmar cutaneous branch produces one or several distal articular branches in an irregular pattern at the level of the scaphoid tubercle.

### ***Musculocutaneous nerve***

At the level of the FCR, about 3 cm proximal to the tip of the radial styloid, the lateral antebrachial cutaneous nerve gives off an articular branch. It re-joins the capsule at the level of the tip of the radial styloid and innervates the periscaphoid joints. There are numerous anastomoses with ramifications of the superficial sensory branch of the radial nerve, the posterior interosseous nerve and articular ramifications of the deep muscular branch of the ulnar nerve.

### ***Medial cutaneous nerve of the forearm***

The medial cutaneous nerve of the forearm sends very thin ramifications towards the deep structures.

## **Surgical Technique**

### ***Total denervation***

The aim of wrist denervation is the division of all the above articular nerve branches, while protecting the main nerve axes from which they arise. The procedure is performed under locoregional anesthesia after the limb has been exsanguinated with the use of a tourniquet placed on the arm. Meticulous hemostasis is achieved with the fine bipolar forceps. Loupes are strongly recommended. Three incisions are required (Fig. 1.15).

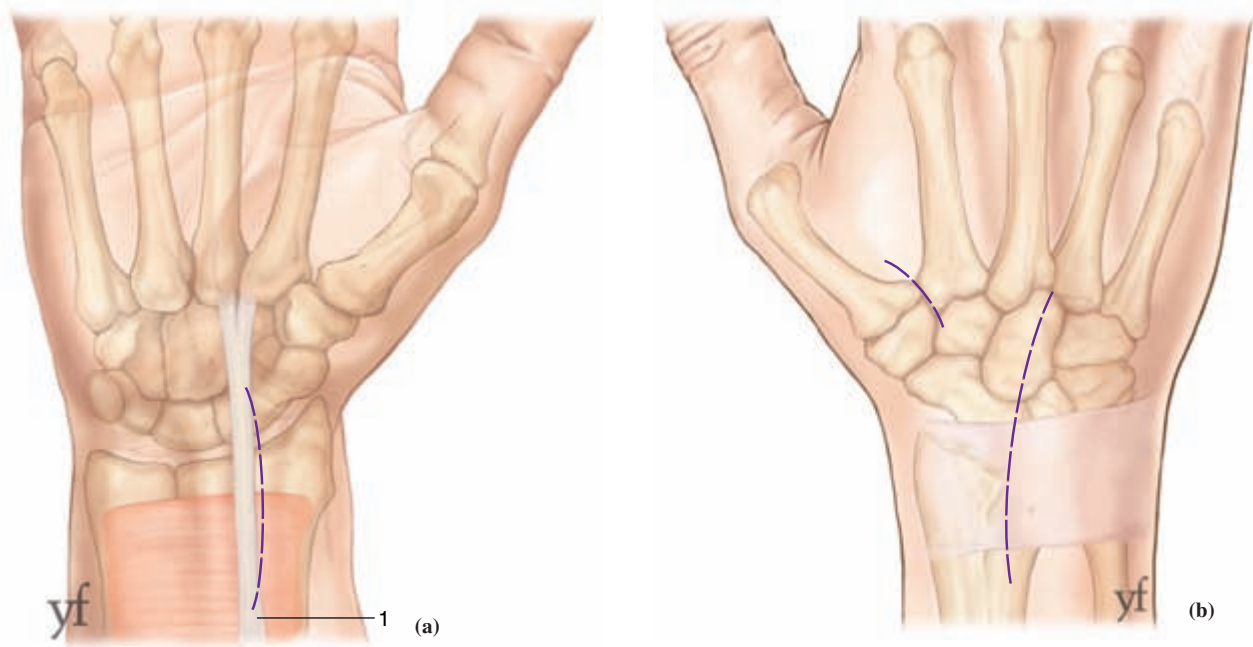
A volar incision using Henry's approach is made, slightly curved with an ulnar concavity, 4 cm long and centered on the radial border of the FCR.

A long dorsal incision is made curved with an ulnar concavity and centered on Lister's tubercle; it starts 3 cm proximal to this point and ends at the base of the third dorsal interosseous space.

A short dorsal incision is made straight or curved, 1.5 cm long, in the first dorsal interosseous space and centered on its proximal summit.

### *Volar incision*

The radial artery is exposed for a distance of 3 cm proximal to the tip of the radial styloid. It is stripped and the venae comitantes are ligated. This ensures that



**Figure 1-15.**

Required incisions at all nerve branches.

(a) Palmar side across the *grand palmar*. (Ref. your text: A volar incision slightly curved with an ulnar concavity, 4 cm long and centered of the radial border of the FCR.)

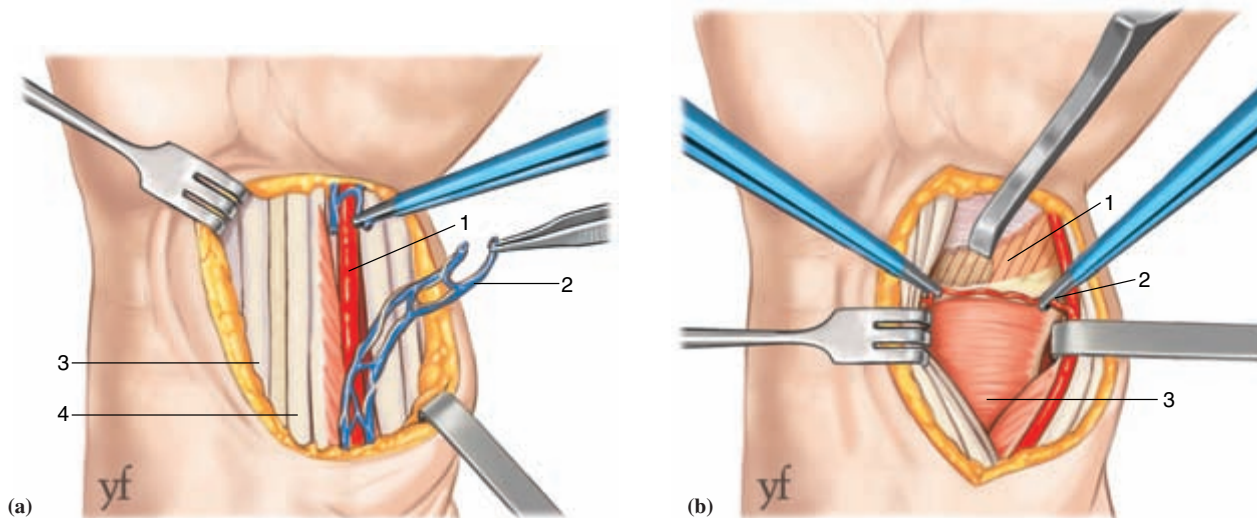
(b) Dorsal side. A dorsal incision straight or curved, 1.5 cm long in the first dorsal interosseous space centered on its proximal summit.

the branches from the lateral antebrachial cutaneous nerve are resected (Fig. 1.16). The next step consists of raising a radial flap just superficial to the antebrachial fascia. At the same time the radial flap is raised progressively to allow dissection with blunt tip scissors. The traction is gentle so as to avoid injury to the superficial branch of the radial nerve. Vertical vessels are thus revealed which connect superficial and deep venous networks, and are accompanied by fine nerve branches. They are electrocoagulated over a longitudinal distance of 1 cm proximal to the radial styloid and transversely up to the axis of the second metacarpal. The third step involves elevating the antebrachial fascia. It is not necessary to visualize the palmar cutaneous branch of the median nerve. Division of its inconstant articular branch is done via blunt finger dissection under the fascia from the distal quarter of the forearm to the first centimeter of the carpal tunnel and medially up to the ulnar nerve and

artery. The fourth stage involves deeper structures, and the distal margin of the pronator quadratus and the distal radius are exposed through retraction of the FPL radially and the digital flexors ulnarly. The proximal carpal arch and its supply from the radial, ulnar and anterior interosseous arteries are coagulated. All the periosteum of the distal radius is elevated along a width of 1 cm, including the most distal insertions of the muscle and the first few millimeters of the capsule, care being taken to avoid any damage to the cartilage. Elevation is carried out more proximal at the level of the distal radioulnar joint to guarantee the division of the medial branch of the anterior interosseous nerve.

#### *Dorsal incision*

The fourth extensor compartment is opened 1 cm ulnar to Lister's tubercle. The exposure is partial and proximal so as to avoid damage to the extensor



**Figure 1-16.**

Main steps for palmar procedures.

(a) Stripping of the radial artery (1) and ligation of venae comitantes (2); Median nerve (3); *Palmaris longus* (4).

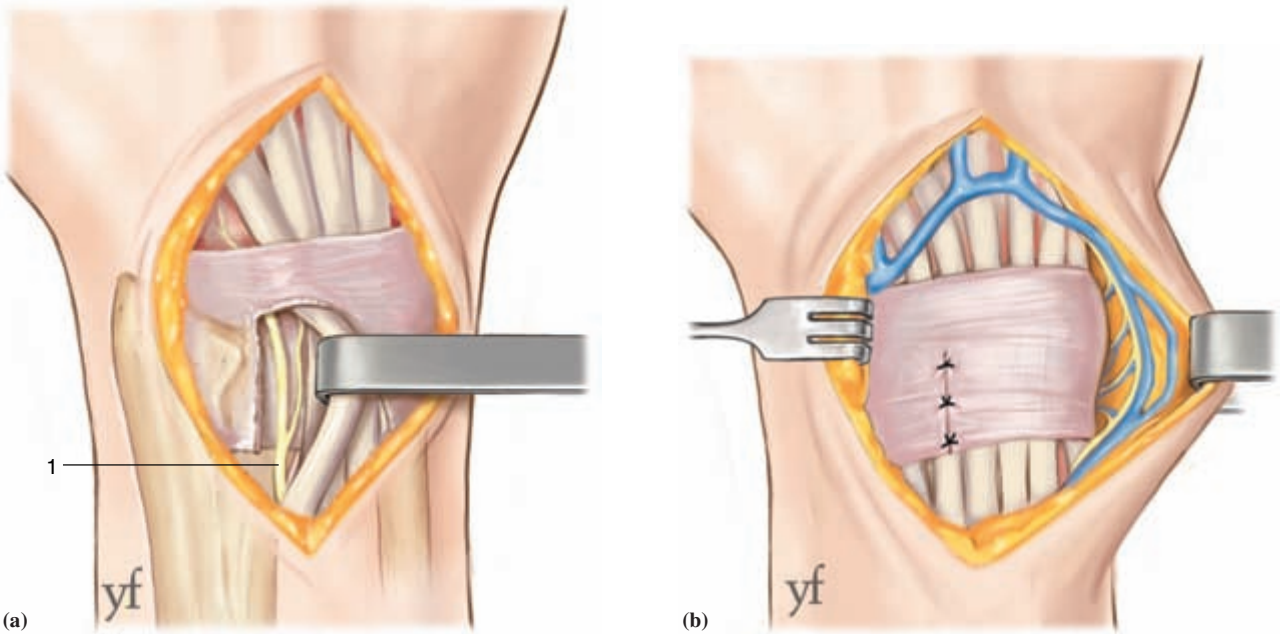
(b) *Ruginage de la marge distale du radius* (1) Hemostasis of the small vessels connecting the deep and superficial vascular systems which are associated with fine nerve ramifications (2). *Pronator quadratus* (3).

retinaculum. Ulnar retraction of the tendons reveals the posterior interosseous nerve and vessels. After hemostasis, the nerve is resected over a distance of 3 cm proximal to the joint line so as to include the branch to the distal radioulnar joint, the latter being sometimes visible (Fig. 1.17). Next, the two borders of the incision are raised as two flaps so as to uncover an area extending over the entire dorsum and distal quarter of the forearm. The radial dissection in fact extends to the area exposed by the volar approach. The palmar dissection is more important as it extends to the flexor carpi ulnaris, and this is so as to divide all the branches arising from the dorsal sensory branch of the ulnar nerve (Fig. 1.18). The same thorough hemostasis and attention to not damaging the main nerves is maintained. This incision allows visualization of the superficial branches of the radial and ulnar nerves as well as their branches on the dorsum of the hand. The metacarpal portion of this incision is used to strip the periosteum of the metacarpal bases, as well as the summits of the 2nd, 3rd and 4th

intermetacarpal bases, while the intermetacarpal arteries are preserved. This step can be omitted if the symptoms are proximal and do not involve the carpometacarpal joints.<sup>17</sup> It is preferable to perform a single incision instead of multiple ones, and any osteophytes can be removed as well.

#### *Dorsal commissural incision*

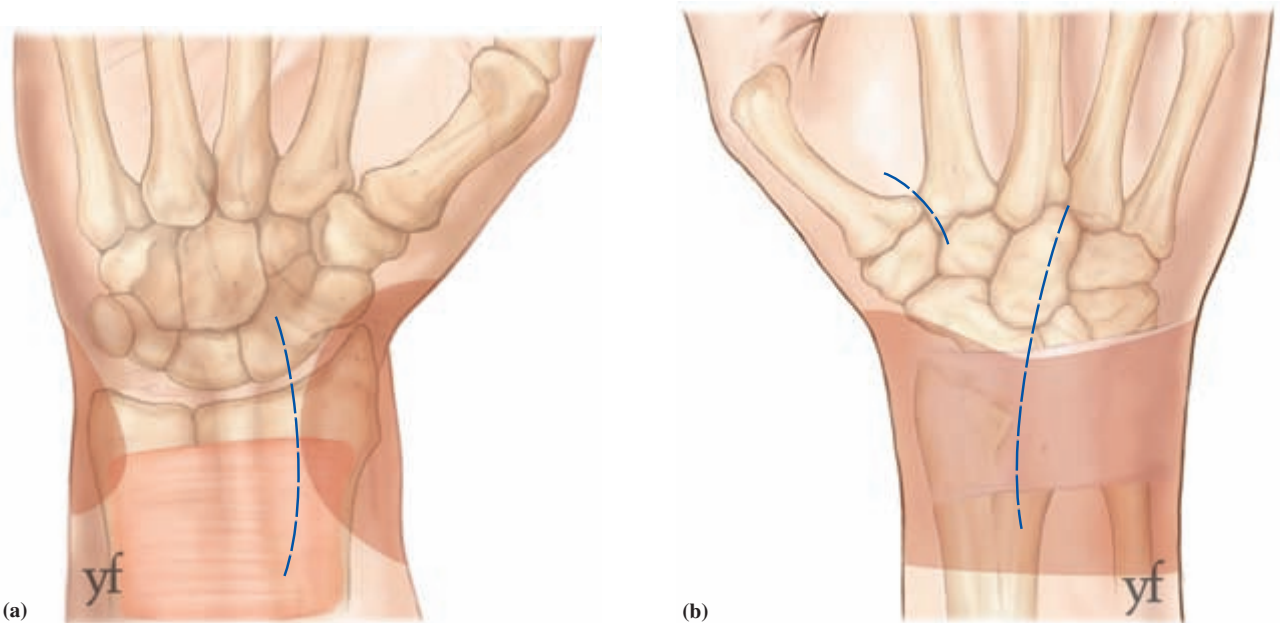
After identification of the vena comitantes which are preserved, the nerve is dissected free and resected over a distance of 1 cm, care being taken not to injure the main trunk. The skin and subcutaneous tissues are separated using blunt finger dissection for a radius of 1.5 cm around the vein. If the nerve is not seen, then the vein must be resected and ligated. Finger dissection is the best method for separating the skin flaps from the deep tissues (Fig. 1.18). Incisions are left opened till the end of the whole operation so as to achieve better hemostasis. If necessary, a perforated drain may be inserted around the radius, from palmar to dorsal, so as to drain all undermined skin.



**Figure 1-17.**

Main steps for dorsal procedures.

- (a) Opening of the 4th compartment and a 3 cm resection of the terminal portion of the posterior interosseous nerve (1).
- (b) Extended detachment with hemostasis of the medial and lateral borders.



**Figure 1-18.**

Required zones of skin separation for releasing ramifications from various cutaneous sensory nerves (a) palmar side; (b) dorsal side.

**Partial or selective denervations**

These involve the anterior and posterior interosseous nerves which form the main supply of the wrist joint.<sup>18</sup> The indications for selective denervation are different and in both cases preoperative assessment with a nerve block as described by Nyakas must be done.<sup>21</sup> The tests are performed as described by Dellon (Fig. 1.19).<sup>6,7</sup>

*Dorsal denervation*

A shorter approach, 2.5 cm long, is centered on Lister's tubercle. The nerve resection is done in the same way as described above.

*Volar denervation*

This is performed via the volar approach and consists of the fourth step, described under volar incision of surgical technique. We find it sensible to add the third step, which is, undermining the antebrachial fascia.

*Mixed dorsal and volar approaches*

This is in effect a minimal complete denervation and is advocated as sufficient by some authors.<sup>24</sup> Berger performs this via a single dorsal approach.<sup>1</sup>

**Postoperative course**

All the undermining results in significant edema which resolves in three to four weeks. We prescribe a resting hand splint for a maximum of one week and advise hand elevation and frequent AROM of the digits. Transient paresthesiae is occasionally observed, especially in the territory of the superficial radial nerve; it disappears after two weeks. Improvement or resolution of wrist pain occurs from the third to fourth week. It will take three to four months, however, before the benefit of denervation becomes clearly evident, and it should be borne in mind that pain continues to improve for a duration of two years.<sup>14,15</sup>

**Complications**

If a meticulous hemostasis has been done, hematoma is rare. Persistent paresthesiae may be a

sign of damage to the superficial radial nerve or one of its branches.<sup>9,12,14</sup> We re-emphasize the importance of handling this nerve with care. No Charcot joint has been reported. This is probably due to the persistence of small branches from nerve anastomoses and those overlooked during surgery.<sup>15</sup> No neuroma has been observed on any of the nerves sectioned by the procedure. The natural history of the osteoarthritis does not seem to be affected by the denervation.<sup>3,12,15</sup>

**Results**

There is no improvement in 10 to 35% of cases, depending on the series. Only Foucher has reported a case in which symptoms worsened after initial improvement over a few months.<sup>13</sup> We have noted this in one case only and consider recurrence to be very uncommon. In most cases, improvement appears long-lasting and Buck-Gramcko reports a case with a 14-year follow up.<sup>2</sup>

**Advantages and disadvantages of complete denervation**

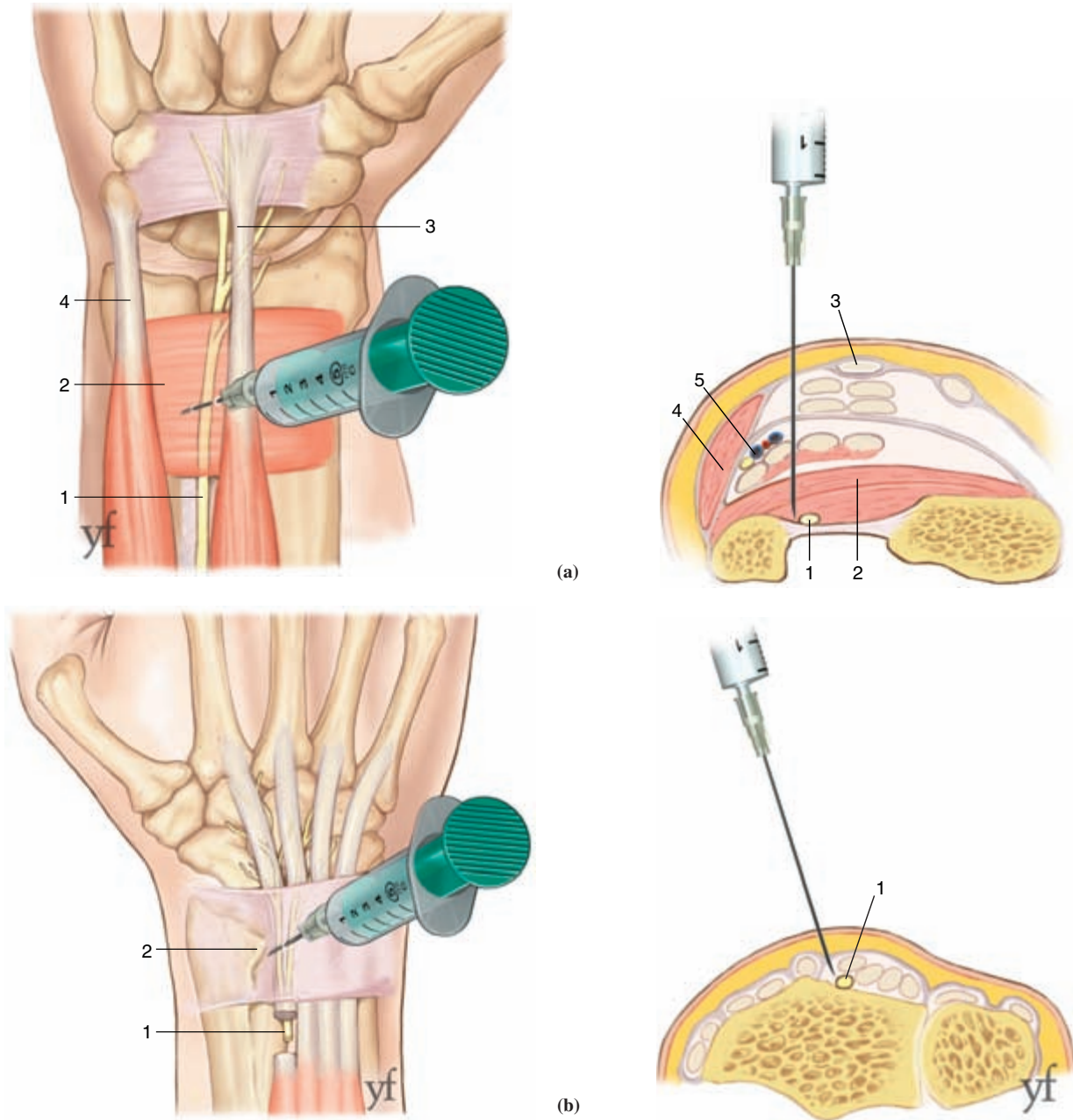
The absence of any bony work does not prejudice against any future therapeutic intervention. It can be performed in a day surgery setting. Follow-up is straightforward and the patient can resume working in three to four weeks. There is no risk of deterioration. In the worse case scenario, the patient has the same pain as before. Where complications are absent, there is no alteration of grip strength or range of motion.<sup>11</sup> The main disadvantage of this procedure is its unpredictability. As such, this must be thoroughly discussed when consent is taken.

**Indications**

It is essential to recognize that partial and complete denervations have different indications.

*Complete denervation*

This is not an undertaking of last resort nor does it compete with wrist arthrodesis; though the indications are similar, the aim is different. The purpose of denervation is to obtain as painless a wrist as possible



**Figure 1-19.**

Nyakas preoperative tests to evaluate area of innervation.

(a) Injection of anterior interosseous nerve (1) by infiltrating beneath the pronator quadratus (2) *Palmaris longus* (3), flexor carpi ulnaris (4), ulnar neurovascular pedicle (5).

(b) Injection of posterior interosseous nerve (1), on ulnar aspect of Lister's tubercle (2).

without the other clinical parameters being affected. A good preoperative assessment in surgery of the wrist includes objective measures of grip strength and range of motion, the degree of radiological change, severity

of pain, the potential of the condition to deteriorate and finally, the demographics and requirements of the patient. The typical indication is a chronically painful wrist in a patient who has a useful range of motion

and grip strength for whom a decrease in pain is the main concern. The pathologies that can be addressed by this surgery are listed in decreasing order: primary osteoarthritis, stage III SNAC or SLAC wrist, post-traumatic arthritis and Kienböck's disease at stage IIIB or IV.<sup>10</sup> In our experience, patients 50-years old and older respond better to denervation. This may be explained by a lesser nerve regeneration potential.

### Partial denervation

In the degenerative wrist, there are very few indications for this form of surgery and its efficacy here is far from proven.<sup>11,13,17,19</sup> The typical indication is pain from nerve irritation due to an adjacent pathology, post-trauma or stretching of the anterior interosseous as described by Dellon.<sup>6,7</sup> In the same way, resection of the posterior interosseous nerve is routine for some surgeons after the posterior approach.<sup>22</sup>

### Conclusion

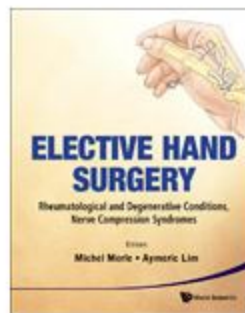
The unusual nature of this procedure does not make it less efficient. There is improvement in 60 to 90% of cases, depending on the series.<sup>4</sup> It is of course imperative to have the correct indication. Modern pain assessment with visual analogue pain scales should allow a more accurate appreciation of operative results.<sup>23</sup>

### References

- Berger RA. (1998) Partial denervation of the wrist: a new approach. *Tech Hand Upper Extrem Surg* 2: 25–35.
- Buck-Gramcko D. (1977) Denervation of the wrist joint. *J Hand Surg* 2B: 54–61.
- Buck-Gramcko D. (1991) Denervation du poignet. In: R Tubiana (ed), *Traite de chirurgie de la main*. Masson, Paris, Vol. IV, pp. 787–792.
- Buck-Gramcko D. (1993) Wrist denervation procedures in the treatment of Kienbock's disease. *Hand Gin* 9: 517–520.
- Cozzi EP. (1991) Denervation des articulations du poignet et de la main. In: R Tubiana (ed), *Traite de chirurgie de la main*. Masson, Paris, Vol. IV, pp. 781–787.
- Dellon AL, Mackinnon SE, Daneshvar A. (1984) Terminal branch of anterior interosseous nerve as source of wrist pain. *J Hand Surg* 9B: 316–322.
- Dellon AL. (1985) Partial dorsal wrist denervation: resection of the distal posterior interosseous nerve. *J Hand Surg* 10A: 527–533.
- Dubert T, Oberlin C, Alnot JY. (1990) Anatomy of the articular nerves of the wrist. Implications for wrist denervation techniques. *Ann Chir Main* 9: 15–21.
- Ekerot L, Holmberg J, Eiken O. (1983) Denervation of the wrist. *Scand J Plast Reconstr Surg* 17: 155–157.
- Ekerot L, Jonsson K, Necking LE. (1986) Wrist denervation and compression of the lunate in Kienbock's disease. *Scand J Plast Reconstr Surg* 20: 225–227.
- Ferreres A, Suso S, Foucher G, et al. (1995) Wrist denervation. Surgical considerations. *J Hand Surg* 20B: 769–772.
- Foucher G. (1989) Technique de denervation du poignet. *Ann Chir Main* 8: 84–87.
- Foucher G, Da Silva JB, Ferreres A. (1992) La denervation totale du poignet. Apropos de 50 cas. *Rev Chir Orthop Repar App Mot* 78: 186–190.
- Foucher G, Da Silva JB. (1992) La denervation du poignet. *Ann Chir Main* 11: 292–295.
- Foucher G, Long Prell P, Erhard L. (1998) La denervation articulaire, une reponse simple ades problemes complexes de chirurgie de la main. *Chirurgie* 123: 183–188.
- Fukumoto K, Kojima T, Kinoshita Y, Koda M. (1993) An anatomic study of the innervation of the wrist joint and Wilhelm's technique for denervation. *J Hand Surg* 18A: 484–489.
- Geldmacher J, Legal HR, Brug E. (1972) Results of denervation of the wrist and wrist joint by Wilhelm's method. *Hand* 4: 57–59.
- Gray DJ, Gardner E. (1965) The innervation of the joints of the wrist and hand. *Anat Record* 151: 261–266.
- Ishida O, Tsai TM, Atasoy E. (1993) Long-term results of denervation of the wrist joint for chronic wrist pain. *J Hand Surg* 18B: 76–80.
- McCarthy CK, Breen TF. (1995) Arborization of the distal posterior interosseous nerve. *J Hand Surg* 20A: 218–220.



21. Nyakas A. (1958) Unsere neue Erfahrungen mit der Denervation des Knochel und tarsalen Gelenkes. *Zbl Chirurgie* **83**: 2243–2249.
22. Tubiana R. (1991) Denervations articulaires. Introduction. In: R Tubiana (ed), *Traite de chirurgie de la main*. Masson, Paris, Vol. IV, p. 780.
23. Voche Ph, Dubert Th, Laffargue C, Gosp A. (2003) Autoevaluation de la douleur et de la fonction du poignet. Proposition d'une version franc; aise d'un questionnaire nord-americain et essai preliminaire. *Rev Chir Orthop* **89**: 443–448.
24. Weinstein LP, Berger RA. (2002) Analgesic benefit, functional outcome, and patient satisfaction after partial wrist denervation. *J Hand Surg* **27A**: 833–839.
25. Wilhem A. (1958) Zur Innervation der Gelenke der oberen Extremitat. *Z Anat EntwicklGesch* **120**: 331–371.
26. Wilhem A. (1966) Die Gelenkdenervation and ihre anatomischen Grundlagen. Ein neues Behanglungsprinzip in der Handchirurgie. *Helv Unlallheilkd* **86**: 1–109.
27. Winckler G. (1953) Le nerf articulaire dorsal du premier espace interosseux de la main. *Arch Anat Histol Embryo* **36**: 61–68.



**Elective Hand Surgery**  
**Rheumatological and Degenerative Conditions,  
Nerve Compression Syndromes**

edited by:

**Michel Merle** (*Hôpital Kirchberg, Luxembourg*),  
**Aymeric Lim** (*National University Hospital,  
Singapore*)

hardcover:

~~US\$198 / £131 / S\$261~~ **US\$148.50 / £98.25 / S\$195.75**

*Free Sample Chapters!*

[Table of Contents \(130 KB\)](#)

[Chapter 1: Wrist Osteoarthritis \(12,022 KB\)](#)

[Chapter 2: Trapeziometacarpal Joint Arthritis \(38,587 KB\)](#)

The volume contains essential information on elective (non-emergency) hand surgery practice. The author, M Merle, a world authority in surgery of the rheumatoid hand, synthesizes the depth of his experience into the book, and presents the management of these conditions in a clear manner. All the elective procedures are described in great detail and depth. The quality of the illustrations is outstanding.

**Save 25%**

till 31 January 2013

Promotional Code:

**WSJAN25A**

**Buy Now**

Find us on:



For more good  
reads:

